

Apresentação invulgar de colite associada ao *Clostridium difficile*

Unusual presentation of Clostridium difficile-associated colitis

Rosa Ferreira¹, Joana Torres¹, Joana Alves², Maria João Pereira¹, Joana Carneiro¹, Sofia Mendes¹, Margarida Ferreira¹, Cláudia Agostinho¹, Edgard Panão¹, Mário Júlio Campos¹

A 67-year-old woman, resident in a nursing home since the age of 41 due to mental retardation, presented in the emergency department with melena followed by hematochezia for the past two days. There was no history of hematemesis, nausea, abdominal pain, diarrhea or fever. She was only on anti-psychotic and anti-epileptic medication.

Physical examination was unremarkable except for pallor and hypotension (95/56mmHg).

Laboratory data revealed anemia of 10.8 g/dL (normal range (NR): 12 - 16), hypoalbuminemia of 26 g/L (NR: 35 - 50) and elevation of C-reactive protein of 11.8 mg/dL (NR: < 0.5).

Upper endoscopy was performed which was normal. Total colonoscopy revealed a tortuous mucosal prominence of purple color, extending longitudinally from the sigmoid to the distal transverse colon, occupying one fifth of the lumen, partially covered with a whitish exudate not removed by vigorous lavage, resembling a colonic varix (Fig. 1). Adjacent mucosa was erythematous and friable, with small whitish exudates, which biopsies showed colonic mucosa with superficial erosion and pseudomembranes with volcanic appearance, composed of fibrin, mucus and neutrophils (Fig. 2), suggesting *Clostridium difficile* (CD) associated colitis. On suspicion of infectious colitis, she started metronidazole 500 mg tid orally during 14 days. No rebleeding episodes were seen. Further evaluation excluded portal hypertension. Follow-up colonoscopy one month later showed complete disappearance of the endoscopic findings and no mucosal lesions. A final diagnosis of CD-associated colitis was established.

Infection from CD occurs when a susceptible host ingests spores of this anaerobic, gram positive bacillus, which colonize the large bowel and release 2 toxins that may cause diarrhea and colitis¹. Although the main risk factor for CD infection is antibiotic use, hospitalization, residence in nursing homes and age greater than 65 years are also predisposing factors^{1,4}. This patient met two of these risk factors. Diarrhea, usually watery, is the main symptom^{2,3}. Rarely, as in this case, there are bloody stools^{2,3}.

Endoscopically, colonic pseudomembranes are almost pathognomonic for CD infection, but are not found in all areas of the colon and may be absent in half of the patients^{2,3}. Pseudomembranes are raised yellow or whitish plaques, up to 2 cm of diameter, which are interspersed with normal mucosa and cannot be removed by lavage². In this case, the pseudomembranes assumed an unusual form, mimicking a colonic varix, an aspect, to our knowledge, not yet described in the literature. Although CD infection may be confirmed by a positive test for CD toxins in stool, false positives and false negatives are not uncommon⁴. In this case, the absence of diarrhea and recent use of antibiotics, associated with atypical endoscopic features led us to start metronidazole prior to the collection of stool samples. Treatment of CD infection involves the evaluation of the clinical and laboratory markers of disease severity^{1,2}. The only treatments

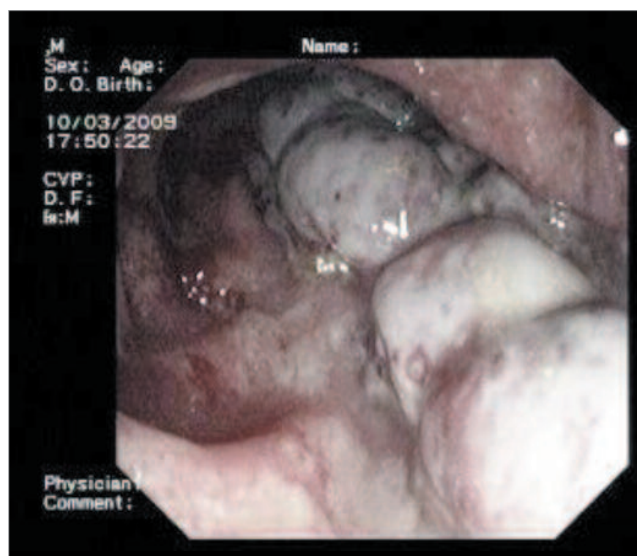


Fig. 1. Colonoscopy showing an apparent varix of the transverse colon with erythematous and friable adjacent mucosa.

¹Serviço de Gastroenterologia, Centro Hospitalar de Coimbra; ²Serviço de Anatomia Patológica, Centro Hospitalar de Coimbra; **Correspondência:** Rosa Ferreira; Rua Carlos Seixas, nº 266, 2ºdto, 3030-177 Coimbra – Portugal; **Telemóvel:** +351 966 510 601; **Fax:** +351 239 800 053; **E-mail:** rosa.l.ferreira@gmail.com; **Recebido para publicação:** 28/07/2010 e **Aceite para publicação:** 20/10/2010.

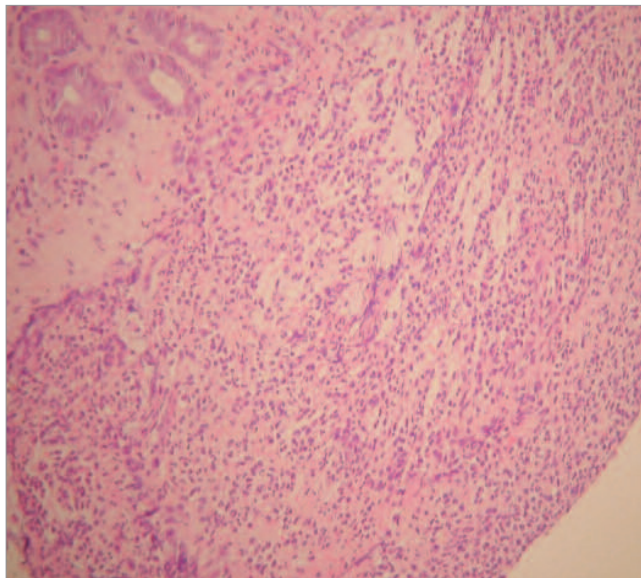


Fig. 2. Pseudomembrane of volcanic appearance composed by fibrin, mucin and neutrophils. (Haematoxylin & eosin, X 400).

proven effective are antibiotic therapy and colectomy for fulminant disease non-responding to antibiotics¹. Although vancomycin is currently considered the first-line treatment in severe CD infection¹, our patient was successfully treated with metronidazole. In summary, this case illustrates an atypical presentation of CD colitis, characterized clinically by gastrointestinal bleeding and endoscopically by pseudomembranes resembling colonic varices.

REFERENCES

1. Leffler DA, Lamont JT. Treatment of Clostridium difficile-associated disease. *Gastroenterology* 2009;136:1899-1912.
2. Hookman P, Barkin JS. Clostridium difficile associated infection, diarrhea and colitis. *World J Gastroenterol* 2009;15:1554-1580.
3. Bartlett JG, Gerding DN. Clinical recognition and diagnosis of Clostridium difficile infection. *Clin Infect Dis* 2008;15:12-18.
4. Durai R. Epidemiology, pathogenesis, and management of Clostridium difficile infection. *Dig Dis Sci* 2007;52:2958-2962.
5. Tonna I, Welsby PD. Pathogenesis and treatment of Clostridium difficile infection. *Postgrad Med J* 2005;81:367-369.